

12 Management of regional lymph nodes in melanoma

All patients with invasive melanoma are at risk for metastasis to the regional lymph nodes. An important part of the follow-up protocol for these patients therefore involves careful examination of the lymph nodes at each follow-up visit. Lymph nodes containing metastatic melanoma often increase in size quickly, sometimes appearing overnight according to the patient. An involved node is usually non-tender and firm to hard in consistency.

The risk of metastasis to lymph nodes is directly related to the Breslow thickness of the primary melanoma.¹ Thus, metastases are rare for thin melanomas (< 0.75mm) and the risk for tumours 0.75–1.0mm thick is about 5%. Intermediate thickness melanomas (1–4mm) have a risk that starts at about 8% for 1mm tumours and this rises steadily to 30% with increasing depth. Melanomas thicker than 4.0mm have a risk of approximately 40% for nodal involvement, in addition to a high risk of systemic spread, but the involved regional nodes are usually not clinically apparent at the time of primary diagnosis.

12.1 Sentinel lymph node biopsy

Since the last publication of these guidelines, a significant body of evidence has accumulated regarding lymphatic mapping and sentinel lymph node biopsy (SLNB). A sentinel node is one that receives lymphatic drainage directly from the primary tumour site. Lymphatic mapping to determine the location of sentinel nodes involves the intradermal injection of a small dose of radioactive tracer at the primary tumour site. At the time of surgery, the surgeon injects patent blue dye adjacent to the primary tumour and identifies the sentinel node as 'hot and blue' through a small incision at the location indicated by the radiologist. The sentinel node is removed and sent for histological examination. Often there may be sentinel nodes in more than one lymph node field, particularly if the tumour is located along the central axis of the torso. Melanomas of the head and neck region regularly drain to more than one zone of the cervical node field.

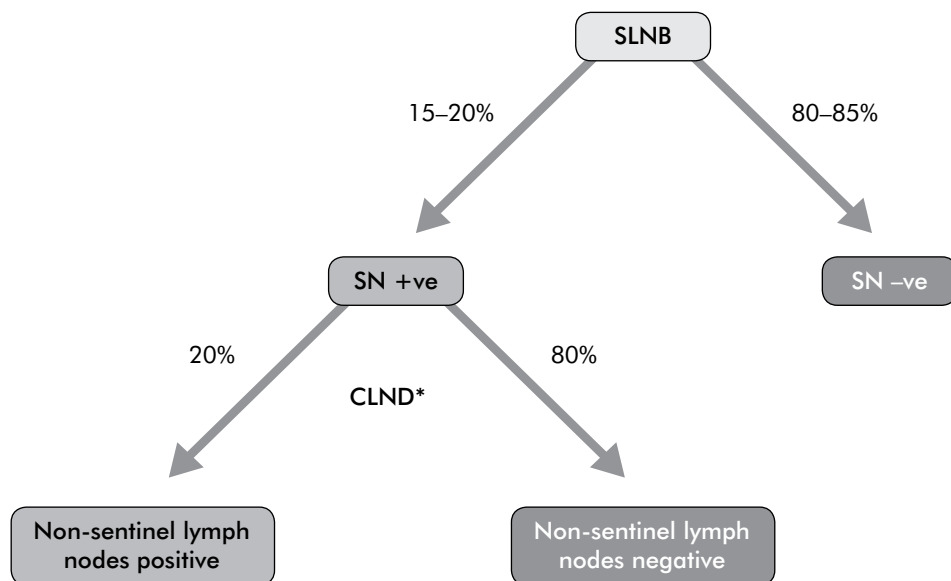
Sentinel node biopsy can be technically demanding, particularly in the head and neck, and should not be undertaken without appropriate training in this technique.² Expert execution and interpretation of the pre-operative lymphoscintigraphy is crucial to the success of the procedure as the failure to correctly identify the sentinel node will be counterproductive to good management of the patient. Furthermore, the pathologist plays a big role in achieving accurate results from a SLNB. The reliability of sentinel node biopsy after prior wide excision is unknown but it may lead to the wrong lymph node being analysed. Patients who are being considered for sentinel node biopsy should be referred before wide local excision of the primary tumour site. If sentinel node biopsy is being considered it is important that lymphatic mapping be done prior to wide excision.

The status of the sentinel node reliably indicates the presence or absence of micrometastases in that node field and is the most accurate prognostic factor in primary melanoma added to the additional prognostic information from the primary lesion.³ An international multicentre randomised controlled trial⁴ (MSLT-1) was designed to assess the outcome of patients with occult metastases detected by SLNB compared with those who received wide local excision alone. The first Multicenter Selective Lymphadenectomy Trial (MSLT-1) randomised 1347 patients with intermediate thickness (1.2–3.5mm) melanomas to the primary aim strata; 1269 of these patients of these patients were evaluable because they accepted the assigned treatment (either wide excision plus post operative observation, with delayed completion lymph node dissection for clinically detectable nodal recurrence; or wide excision plus SLNB, with immediate completion lymph node dissection for sentinel node metastases. An additional 647 patients with lesions thinner than 1.2mm (low risk of nodal metastases) and thicker than 3.5mm (high risk of distant metastases at initial diagnosis) were enrolled to evaluate surgical morbidity and accuracy of the procedure, but were considered unlikely to exhibit survival differences based on modelling from the John Wayne Cancer Institute's database.⁵ In the primary aim group of patients with intermediate thickness melanomas (where the risk of a positive sentinel lymph node is 15–20%, Figure 3) the results of the third of five planned interim analyses were as follows; five-year melanoma-specific survival rates were similar in the two groups ($87.1 \pm 1.3\%$ and $86.6 \pm 1.6\%$, respectively) (hazard ratio, 0.92; 95% CI, 0.67–1.25; $P = 0.58$). The five year survival rate for sentinel node positive patients was $72.3 \pm 4.6\%$ and $90.2 \pm 1.3\%$ for node negative patients (hazard ratio for death, 2.48; 95% CI, 1.54–3.98; $P < 0.001$). The mean estimated five-year disease-free survival rate was $78.3 \pm 1.6\%$ in the biopsy group and $73.1 \pm 2.1\%$ in the observation group (hazard ratio, 0.74; 95% CI, 0.59–0.93; $P = 0.009$). The five-year survival was significantly higher in the group that underwent immediate lymph node dissection for a positive sentinel node compared to the group who underwent nodal observation and had delayed lymphadenectomy for clinically apparent nodal metastases ($72.3 \pm 4.6\%$ vs. $52.4 \pm 5.9\%$; hazard ratio for death, 0.51; 95% CI, 0.32–0.81; $P = 0.004$). This statistic was not a primary outcome point in the original study design but it was a predetermined secondary outcome measure. The results of the interim analyses of this study and the interpretation of the data therein are still actively being debated.⁶

Preliminary information from the 4th interim analysis (median follow-up 59.5 months) confirms the results of the 3rd interim analysis and also shows a statistically significant lower rate of distant metastasis in the sentinel lymph node biopsy group (18.1% vs 21.2%) compared with wide local excision and observation.⁵

There is still no overall survival advantage shown at this time.

Figure 3 Distribution of lymph node metastases for melanomas 1.2–3.5mm thick



*CLND = completion lymph node dissection

Sentinel node biopsy should be discussed with patients who have a primary tumour 1.2–3.5mm thick. In addition, there are other patients with thinner tumours who are at particular risk of having a positive sentinel node. Therefore SLNB may be discussed with patients with melanomas 0.75–1.2mm thick based on the characteristics of the primary tumour, such as ulceration, Clark level (IV or V), or a high mitotic rate.⁷ Where the true Breslow thickness cannot be determined, usually because the melanoma was diagnosed by shave biopsy, patients may also be offered SLNB. The risk of micrometastatic disease is inversely related to the patient's age and those younger than 35 years with a thin primary may benefit from sentinel node biopsy.⁸ Patients with thick primaries (4mm or greater) are at substantial risk of developing disseminated metastatic disease. However, the status of the sentinel node in these patients is still the most important prognostic factor in this group of patients and biopsy may be recommended to assist in determining prognosis and to improve local disease control.⁹

Evidence summary	Level	References
Sentinel lymph node status provides accurate prognostic information for disease-free and overall survival for melanomas stage T1b ¹⁰ or greater	I	1, 3
To date, the MSLT-1 study shows no overall survival benefit	II	4, 5
Patients undergoing SLNB have a significantly lower rate of distant metastasis compared with wide local excision and observation	II	5
The interim results of the MSLT-1 study shows a potential survival benefit to patients with 1.2–3.5mm thick melanomas with positive sentinel lymph nodes who undergo immediate completion lymphadenectomy compared to those in the control group who undergo clinical observation and develop nodal recurrence	III-2	4
Sentinel node biopsy can be technically demanding and requires specialised expertise and resources	III-1	2

Recommendations

	Grade
1. Patients with a melanoma greater than 1.0mm in thickness be given the opportunity to discuss sentinel lymph node biopsy to provide staging and prognostic information	C
2. SLNB be performed only, following a full discussion of the options with the patient, in a unit with access to appropriate surgical, nuclear medicine and pathology services	C

12.2 Therapeutic lymph node dissection

Therapeutic lymph node dissection is an operation involving the radical clearance of a lymphatic field and, in melanoma, is indicated for the presence of metastatic lymphadenopathy. Lymph node metastasis detected during clinical observation should be confirmed by guided fine needle biopsy of the suspicious node. Ultrasound imaging and guide FNB by a clinician experienced in the examination of lymph nodes may serve to increase the sensitivity of this procedure. A negative fine needle biopsy is not conclusive and should be repeated if the node remains clinically suspicious after a period of observation of one month. Only in centres where cytological diagnosis is unavailable, or if needle biopsy is unhelpful, is open biopsy recommended. If open biopsy is deemed necessary, the biopsy incision should be placed so that it can be easily excised in continuity with the lymph node field if radical lymphadenectomy is subsequently performed.

For patients with a positive SLN current practice is completion lymph node dissection.

However it is not known how to best manage patients with micrometastases detected by SLNB. This question is currently being investigated by MSLT-II, in which patients with histopathological or molecular (RT-PCR) evidence of tumour in the sentinel node are randomly assigned to receive completion lymph node dissection or observation.¹¹ MSLT-II is ongoing and the results are not yet available.

A systematic review of randomised controlled trials comparing elective lymph node dissection with surgery delayed until the time of clinical recurrence showed no significant overall survival benefit for patients undergoing elective lymph node dissection.¹² Therefore, except in rare circumstances, elective lymph node dissection is not recommended for melanoma patients.

Radical lymph node dissections for melanoma are relatively difficult operations and should be undertaken only by surgeons appropriately trained for the operation. There is a substantial risk of recurrence in dissected node fields in patients with clinically positive lymph nodes and only a thorough formal dissection will substantially lower the risk of recurrence in a dissected node field. A dissection can only be deemed thorough if it includes levels I–III in the axilla and a complete clearance of the femoral triangle nodes in the groin.⁷ Extended procedures that include removal of the pectoralis minor muscle in the axilla and superficial parotidectomy in the neck should be considered. When dealing with lymphatic metastases in the groin, consideration should be given to the status of the ipsilateral external iliac and obturator nodes in the pelvis. Extension of the inguinal dissection to include the nodes in the pelvis, an ilio-inguinal dissection, may be indicated in the following circumstances: evidence of involvement of the pelvic nodes on staging investigations; gross clinical involvement or evidence of involvement in three or more nodes in the inguinal region; clinically suspicious nodes high in the groin.^{7,13} Therapeutic neck dissection in melanoma patients carries a high risk of recurrence in the nodal field. This is a difficult operation, fraught with complications, and specific training is essential to achieve the optimal outcome. Even when surgeons with specific training undertake this dissection, the incidence of recurrence in the neck is considerable (up to 28%). Postoperative radiation therapy could be considered if the pathology report indicates matted nodes, extracapsular spread, and large size and/or large number of involved nodes.^{14,15} (Refer to Chapter 13 *Management of locoregionally recurrent melanoma*).

All patients with positive lymph nodes are at high risk for systemic dissemination. It is therefore important to arrange consultation with a multidisciplinary melanoma treatment centre if possible.¹⁶ Refer to Chapter 18 *Multidisciplinary care of melanoma*. Even where minimal involvement of the lymph nodes is found on node dissection, a referral of these patients to a melanoma centre may allow them to enrol or participate in clinical trials of adjuvant therapies. Refer to Chapter 13 *Management of locoregionally recurrent melanoma* for a discussion of the evidence regarding this treatment modality for lymph node metastases.

Evidence summary	Level	References
Elective lymph node dissection is not recommended, regardless of the Breslow thickness of the primary tumour	I	7, 12
Completion lymphadenectomy can result in complications in about a third of patients – most of these are minor but the rate of clinically significant lymphoedema following axillary or groin dissection is 5–10%	IV	2
All patients with positive lymph nodes are at high risk for systemic dissemination. It is therefore important to arrange consultation with a multidisciplinary melanoma treatment centre if possible	IV	16

Recommendations

	Grade
3. Patients who have positive sentinel lymph node biopsy be offered completion lymphadenectomy, or be referred to a specialist centre for discussion of further treatment options	C
4. Therapeutic node dissection be offered to all patients with evidence of metastatic nodal disease after excluding stage IV disease using appropriate investigations	C

12.3 Good practice points

- A therapeutic node dissection includes a full levels (I to III) clearance in the axilla. A therapeutic neck dissection may include a superficial parotidectomy as clinically indicated
- Patients with inguinal node metastases be considered for clearance of the intra-pelvic iliac and obturator nodes when the staging investigation demonstrates evidence of involvement
- Elective clearance of the pelvic nodes be considered when there is gross macroscopic disease in the inguinal node field or there are three or more histologically positive nodes below the level of inguinal ligament
- Patients with lymph node metastases be offered discussion with a multidisciplinary team with a view to enrolment in clinical trials

References

1. Lens MB, Dawes M, Newton-Bishop JA, Goodacre T. Tumour thickness as a predictor of occult lymph node metastases in patients with stage I and II melanoma undergoing sentinel lymph node biopsy. *Br J Surg* 2002; 89(10):1223–1227.
2. Morton DL, Hoon DS, Cochran AJ, Turner RR, Essner R, Takeuchi H et al. Lymphatic mapping and sentinel lymphadenectomy for early-stage melanoma: therapeutic utility and implications of nodal microanatomy and molecular staging for improving the accuracy of detection of nodal micrometastases. *Ann Surg* 2003; 238(4):538–549.
3. Balch CM, Soong SJ, Gershenwald JE, Thompson JF, Reintgen DS, Cascinelli N et al. Prognostic factors analysis of 17,600 melanoma patients: validation of the American Joint Committee on Cancer melanoma staging system. *J Clin Oncol* 2001; 19(16):3622–3634.
4. Morton DL, Thompson JF, Cochran AJ, Mozzillo N, Elashoff R, Essner R et al. Sentinel-node biopsy or nodal observation in melanoma. *N Engl J Med* 2006; 355(13):1307–1317.
5. Morton DL, Cochran AJ, Thompson JF. The rationale for sentinel node biopsy for melanoma. In press. *Nature Clinical Practice Oncology*.
6. Thomas JM. Sentinel lymph node biopsy in malignant melanoma. *BMJ* 2008; 336(7650):902–903.
7. National Comprehensive Cancer Network. Melanoma: Clinical Practice Guidelines in Oncology. version 2. 2007. National Comprehensive Cancer Network.
8. Sondak VK, Taylor JM, Sabel MS, Wang Y, Lowe L, Grover AC et al. Mitotic rate and younger age are predictors of sentinel lymph node positivity: lessons learned from the generation of a probabilistic model. *Ann Surg Oncol* 2004; 11(3):247–258.
9. Gershenwald JE, Mansfield PF, Lee JE, Ross MI. Role for lymphatic mapping and sentinel lymph node biopsy in patients with thick (> or = 4 mm) primary melanoma. *Ann Surg Oncol* 2000; 7(2):160–165.
10. Balch CM, Buzaid AC, Soong SJ, Atkins MB, Cascinelli N, Coit DG et al. Final version of the American Joint Committee on Cancer staging system for cutaneous melanoma. *J Clin Oncol* 2001; 19(16):3635–3648.
11. Amersi F, Morton DL. The role of sentinel lymph node biopsy in the management of melanoma. *Adv Surg* 2007; 41:241–56.:241–256.
12. Lens MB, Dawes M, Goodacre T, Newton-Bishop JA. Elective lymph node dissection in patients with melanoma: systematic review and meta-analysis of randomized controlled trials. *Arch Surg* 2002; 137(4):458–461.
13. Coit DG, Brennan MF. Extent of lymph node dissection in melanoma of the trunk or lower extremity. *Arch Surg* 1989; 124(2):162–166.
14. Stevens G, Thompson JF, Firth I, O'Brien CJ, McCarthy WH, Quinn MJ. Locally advanced melanoma: results of postoperative hypofractionated radiation therapy. *Cancer* 2000; 88(1):88–94.
15. Burmeister BH, Smithers BM, Burmeister E, Baumann K, Davis S, Krawitz H et al. A prospective phase II study of adjuvant postoperative radiation therapy following nodal surgery in malignant melanoma – Trans Tasman Radiation Oncology Group (TROG) study 96.06. *Radiother Oncol* 2006; 81(136):142.
16. Johnson TM, Chang A, Redman B, Rees R, Bradford C, Riba M et al. Management of melanoma with a multidisciplinary melanoma clinic model. *J Am Acad Dermatol* 2000; 42(5 Pt 1):820–826.

